

KEY FACTS

IMAGING

• Multiparametric MR (mpMR)

- Combination of anatomical and functional imaging
- Anatomical imaging
 - T2WI
 - Lesion detection and characterization; gland volume and extraprostatic extension
 - T1WI
 - Rule out prostatic hemorrhage (tumor mimicker)
- Functional imaging
 - Diffusion-weighted imaging (DWI)
 - Apparent diffusion coefficient map (ADC)
 - Interpretation of combined high b-value ($\geq 1,400$ s/mm²) DWI and ADC map
 - Lesion detection and characterization
 - Dynamic contrast-enhanced (DCE) study
 - Multiple T1WI obtained during and after IV injection of contrast








- Key sequence for assessment of tumor recurrence
- MR spectroscopy (MRS)
 - Key metabolic compounds in prostate gland: Citrate [2.60 parts per million (ppm)]; creatine (3.04 ppm); choline (3.20 ppm)

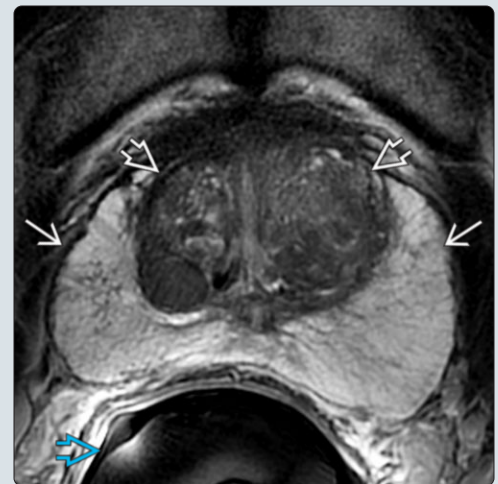
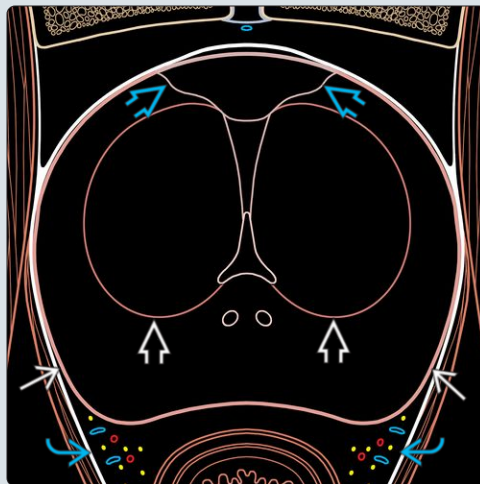
○ Technical notes



- Scanner: $\geq 1.5T$
- Coils: Surface multichannel phased array \pm endorectal
- At least 6 weeks after prostate biopsy

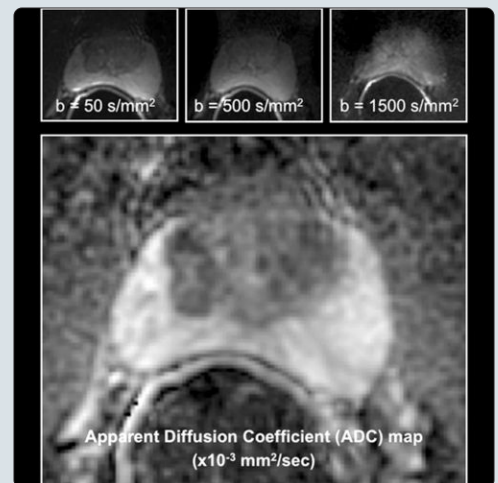
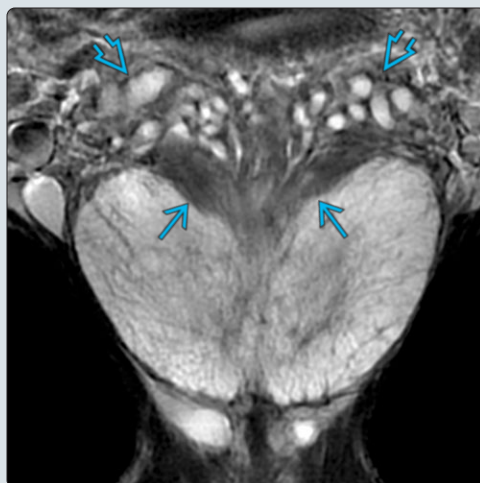
• Normal prostate gland

- Peripheral zone
 - 70% of gland volume
 - High and homogeneous signal intensity (SI) on T2WI
- Transition zone
 - 5% of gland volume
 - In benign prostatic hyperplasia (BPH), volume increases and SI on T2WI is heterogeneous ("organized chaos")
- Central zone: 25% of gland volume (\downarrow in BPH)

(Left) Medical illustration shows an axial view through the midprostate. The visualized key anatomical structures include peripheral zone , transition zone , neurovascular bundles , and anterior fibromuscular stroma . (Right) Axial T2WI MR of the prostate through the midgland is shown. The peripheral zone  shows high signal intensity (SI) given the water content in the normal gland. The transition zone  shows heterogeneous SI in this subject with mild BPH. This image was obtained using an endorectal coil .



(Left) Coronal T2WI MR shows the prostate in the same patient. Central zone appears as a triangular or V-shaped hypointense structure  in the posterosuperior portion of the gland. The seminal vesicles  appear as hyperintense tubular structures. (Right) Composite figure shows axial DWI MR (at different b-value) and ADC map. The SI on DWI reflects the motility of water molecules. It is key for cancer detection. The \uparrow cellularity of tumor restricts water diffusion, resulting in \uparrow SI on high b-value DWI and \downarrow SI on ADC map.



TERMINOLOGY

Abbreviations

- Multiparametric MR (mpMR)
- Signal intensity (SI)
- Peripheral zone (PZ)
- Transition zone (TZ)
- Central zone (CZ)
- Diffusion-weighted imaging (DWI)
- Apparent diffusion coefficient (ADC)
- Magnetic resonance spectroscopy (MRS)

Definitions

- MR study composed of anatomical and functional imaging

IMAGING

MR Findings

- T1WI
 - Main role: Exclusion of postbiopsy hemorrhage is potential mimicker for malignancy
 - Evaluation of pelvic lymphadenopathy
- T2WI
 - Anatomical imaging
 - Multiplanar acquisition
 - Key role in tumor detection and staging
 - Normal prostate
 - PZ: 70% of gland volume, high and homogeneous SI
 - TZ: 5% of gland volume, in benign prostatic hyperplasia (BPH), volume increases and SI on T2WI is heterogeneous ("organized chaos")
 - CZ: 25% of gland volume (↓ in BPH)
 - Cancer: Mass with low SI
- DWI
 - Functional imaging
 - SI based on motion restriction of water molecules
 - Key role in lesion characterization and detection
 - Interpretation of combined high b-value ($\geq 1,400$ s/mm²) DWI and ADC map
 - Cancer: High SI on high b-value DWI and low SI on ADC map
 - ADC values correlate with tumor grading (lower ADC value in higher Gleason score)
- T1WI C+
 - Dynamic contrast-enhanced (DCE) study
 - Multiple T1WI obtained during and after IV injection of contrast
 - Role in lesion characterization/detection
 - Key role in assessment of tumor recurrence after prostatectomy
 - Imaging interpretation
 - Qualitative analysis: Most commonly used, based on assessment of enhancement of lesion compared to surrounding gland
 - Cancer typically shows higher and earlier enhancement than surrounding gland
 - Semiquantitative analysis: Curves of enhancement
 - Type 1: Progressive enhancement
 - Type 2: Upslope followed by plateau
 - Type 3: Upslope followed by decline, most specific for cancer

- Type 3: Upslope followed by decline, most specific for cancer
- Quantitative analysis: Pharmacokinetic modeling
 - K-trans (volume transfer constant) and K-ep (reverse reflux rate constant) are increased in cancer

- MRS
 - Role in assessment of tumor aggressiveness and response to treatment
 - Limited role in tumor detection (compared to T2WI+DWI and DCE)
 - Key metabolic compounds in prostate gland
 - Citrate [2.60 parts per million (ppm)]
 - Creatine (3.04 ppm)
 - Choline (3.20 ppm)
 - Cancer
 - ↑ choline and ↓ citrate; ↑ choline-plus-creatine to citrate ratio (CC:C)
- Common cancer mimickers
 - Prostatitis
 - Inflammation in PZ reduces SI on T2WI
 - Helpful tip: Inflammation usually shows a non-mass-like and ill-defined appearance
 - BPH nodules
 - Stromal nodules may restrict diffusion
 - Helpful tip: Benign nodules are usually well-defined on T2WI
 - Hemorrhage (post biopsy)
 - Hemorrhage may appear as low SI on T2WI
 - Helpful tip: High SI on T1WI
 - CZ
 - On axial T2WI at base of gland, it may appear with round/oval shape and low SI
 - Helpful tip: Coronal images demonstrate triangular (teardrop- or butterfly-shaped) appearance

Imaging Recommendations

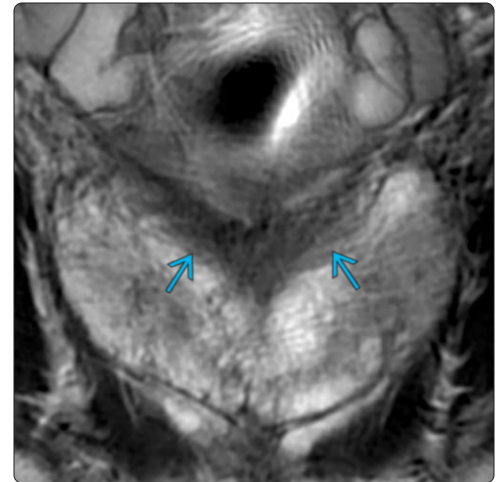
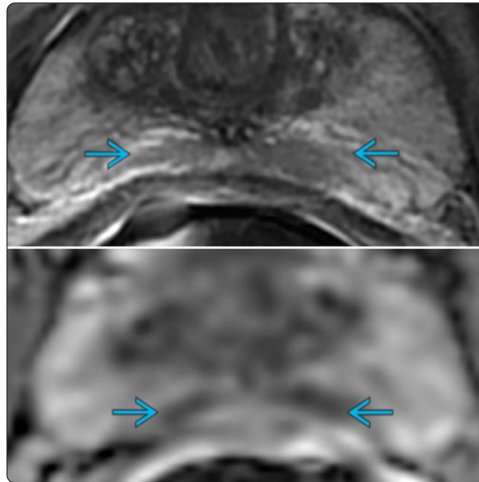
- Protocol advice
 - Scanner: $\geq 1.5T$
 - Coil: Surface multichannel phased array \pm endorectal
 - Timing: At least 6 weeks after biopsy
 - Sequences
 - Multiplanar high resolution T2WI
 - DWI with multiple b-values, high b-value ≥ 1400 s/mm²
 - DCE with temporal resolution < 10 sec

DIAGNOSTIC CHECKLIST

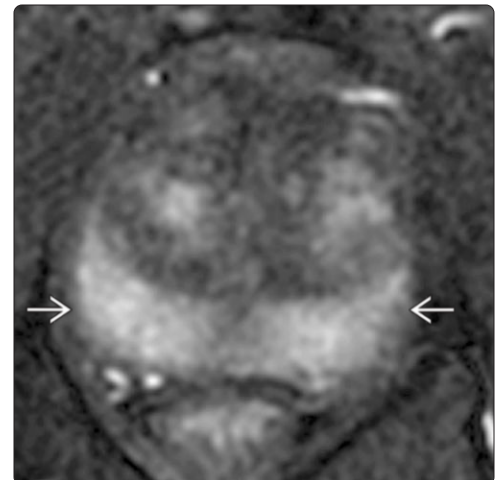
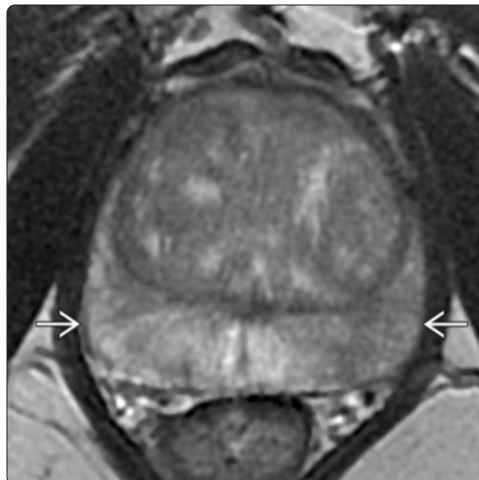
Reporting Tips

- Prostate Imaging Reporting and Data System (PI-RADS)
 - Current version: PI-RADS v2
 - Main aim: Standardization of acquisition and interpretation of mpMR of prostate
 - Findings are classified in 5 categories of risk for clinically significant cancer (from PI-RADS 1: Very low risk, to PI-RADS 5: Very high risk) based on appearance on T2WI, DWI, and DCE

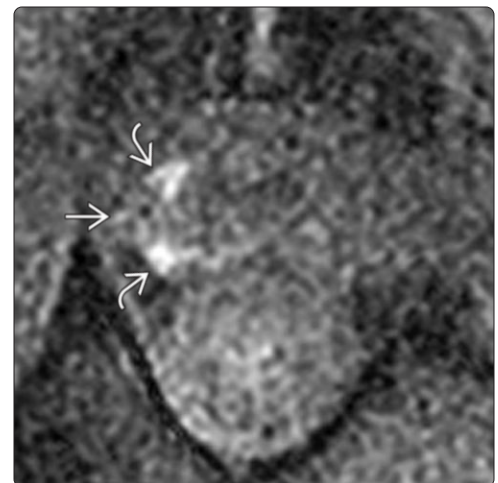
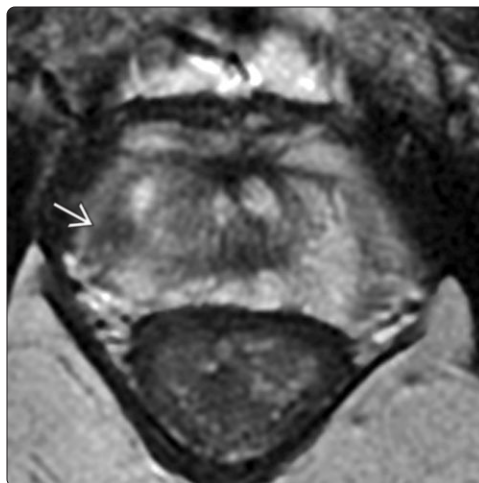
(Left) Axial T2WI MR (top) and ADC map (bottom) show symmetric ovoid structures of low signal intensity projecting over the peripheral zone of the base. (Right) Coronal T2WI in the same patient confirms those structures to be the central zone. The central zone typically appears as a symmetric V-shaped structure on coronal images. On axial images, the central zone may mimic cancer because of low signal intensity on T2WI and ADC map.

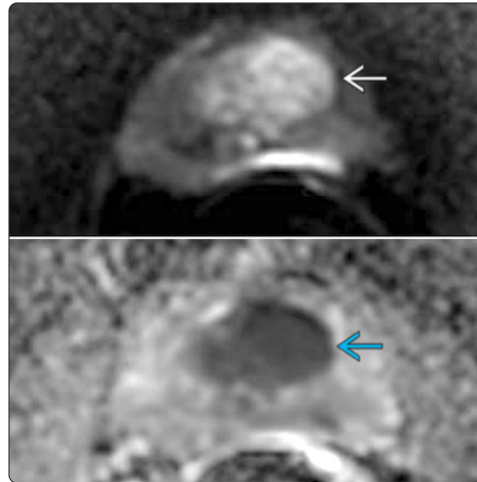
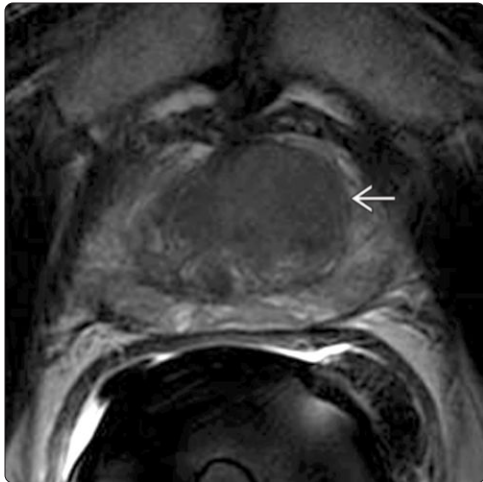

(Left) Axial T2WI MR shows the prostate in a 66-year-old man presenting with increased PSA (6.8 ng/mL). The peripheral zone shows ill-defined, decreased signal intensity. (Right) Axial postcontrast T1WI MR at the same level reveals diffuse hyperenhancement of the peripheral zone. Prostate biopsy demonstrated acute on chronic prostatitis. Inflammation is a common cancer mimicker because it is associated with decreased signal intensity on T2WI.

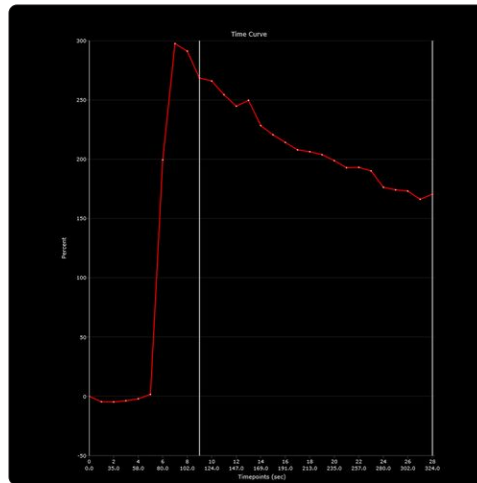
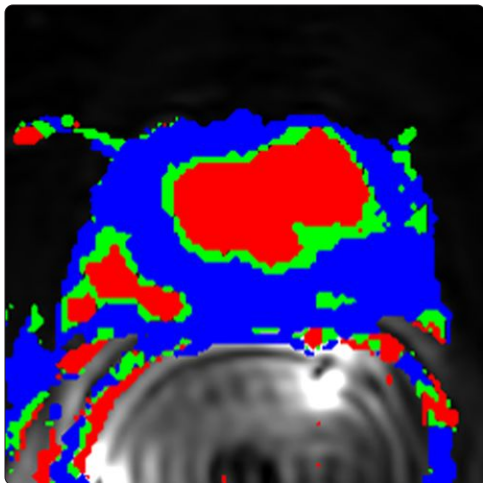


(Left) Axial T2WI MR shows the prostate in a 67-year-old man with history of prostate cancer (Gleason score 3+4 = 7) on a recent systematic biopsy. The cancer is a low signal intensity mass located in the posterolateral aspect of the peripheral zone. (Right) Axial T1WI MR obtained at the same level shows an area of high signal intensity corresponding to postbiopsy hemorrhage. Note that the area with cancer does not show high signal intensity. This appearance, defined as a halo sign, is highly specific for cancer.

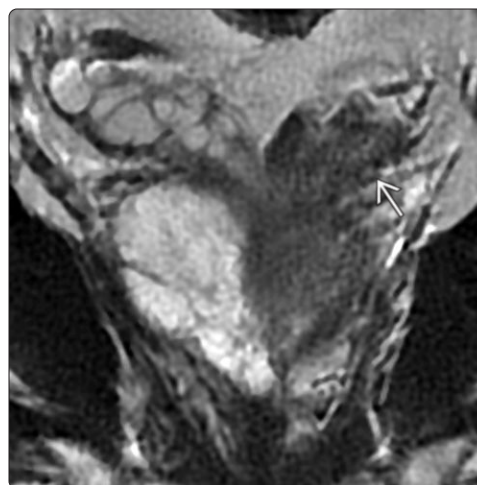
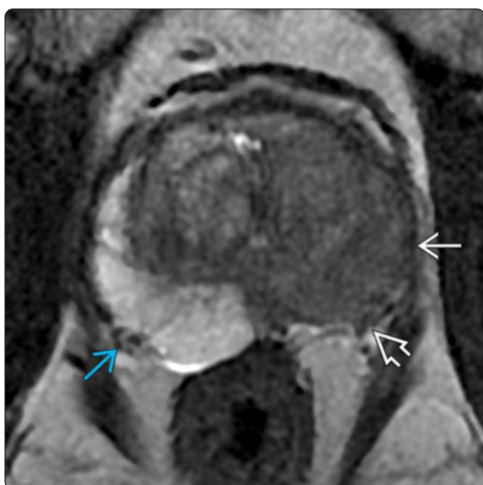




(Left) Axial T2WI MR of the prostate in a 64-year-old man presenting with elevated PSA (24 ng/mL) shows a large mass of low signal intensity in the anterior transition zone. Target biopsy revealed adenocarcinoma, Gleason score 5+4 = 9. (Right) The cancer shows high signal intensity on the high b-value DWI (top) and low signal intensity on the ADC map (bottom portion). DWI/ADC represents the key functional technique in an mpMR study of the prostate.



(Left) Color-coded map is based on curves of enhancement. The cancer is displayed with the color red corresponding to a type 3 curve (upslope followed by decline). Cancer typically shows a higher and earlier enhancement than the normal gland. (Right) Type 3 curve of enhancement (wash-in followed by washout) is the most specific for cancer.



(Left) Axial T2WI MR of the prostate in a 70-year-old man presenting with elevated PSA (16.8 ng/mL) shows a large mass of low signal intensity in the peripheral zone of the left midgland. At prostatectomy, the mass was adenocarcinoma, Gleason score 5+4 = 9 with extraprostatic extension. Note the tumor involvement of the left neurovascular bundle (NVB). The right NVB is normal. (Right) Coronal T2WI MR of the prostate in the same patient reveals tumor extension into the left seminal vesicle.